



PATIENT

Missy Ortell

SPECIES

Canine

BREED

Sheperd Mix

SEX

FS

AGE

13 years

WEIGHT

80lbs

INTERPRETED BY

Maggie Machen Lamy,
DVM, DACVIM
(Cardiology)

IMAGING PERFORMED BY

JK

HOSPITAL NAME

Hamburg VC

REFERRING VET

Dr. Branning

INVOICE

23661

DATE

4/14/22

PRESENTING CLINICAL SIGNS

History: Coughing, breathing heavy, poor appetite, arrhythmia. Enlarged heart and pericardial fluid suspected on CXR.

Abnormal PE/Chem/CBC/UA Results: BP 184/158(165), 173/105(119)

ECHOCARDIOGRAM FINDINGS

2D, m-mode, color flow and doppler imaging is available. Large volume pericardial effusion with diastolic collapse of the right atrial wall consistent with cardiac tamponade. Hypoechoic well-demarcated mass lesion associated with the right AV groove (see below). LV function is adequate. Left atrium is normal in diameter. LV is decreased in dimension with adequate function. LV wall thicknesses are increased consistent with volume depletion. The pulmonic and aortic valves are normal in appearance. Normal outflow velocities. Large volume pericardial effusion. Small volume pleural effusion. Ascites seen on subcostal.

CARDIAC CHART

CANINE CARDIAC PARAMETERS	MR VMAX (m/s)	TR VMAX (m/s)	LA/AO (Boon method)	LA/AO (Heart Base; Swe)	FS (%)	EF (%)	EPSS (cm)	
NORMAL PARAMETER	4.5-5.5	<2.7	1.3	<1.6	28-40	40-100	<0.6	
PATIENT	5.0	NA	1.2	1.1	46	78	NM	
CANINE CARDIAC PARAMETERS	HR (BPM)	AV VMAX (m/s)	PV MAX (m/s)	BODY WEIGHT (kg)	LA 2D short axis Base view (cm)	LVIDd Avg; 2D and m-mode short axis (cm)	LVIDs Avg; 2D and m-mode short axis (cm)	
NORMAL PARAMETER	50-100	0.7-1.7	0.7-1.6	BELOW	BELOW	BELOW	BELOW	
PATIENT	250	0.72	1.2	36.3	3.2	3.5	1.9	
*Normal chamber parameters expressed as a mean value (SD)					3	1.27 (5.3)	2.46 (2.46)	1.36 (5.5)
BODY WEIGHT DEPENDENT PARAMETERS					5	1.40 (4.5)	2.74 (5.2)	1.60 (4.7)
<i>*Note: All measurements based upon multi-modal images and methods. An average value is reported.</i>					10	1.50 (3.8)	3.27 (3.5)	2.06 (3.1)
					15	1.83 (2.0)	3.71 (2.4)	2.43 (2.1)
					20	2.02 (1.9)	4.14 (2.2)	2.80 (2.0)
					25	2.18 (2.4)	4.48 (2.9)	3.10 (2.5)
					30	2.33 (3.3)	4.83 (3.9)	3.39 (3.4)
					35	2.48 (4.3)	5.17 (5.0)	3.69 (4.5)
					40	2.62 (5.2)	5.48 (6.1)	3.96 (5.4)
					50	2.88 (7.1)	6.07 (8.3)	4.46 (7.4)

Adapted from June Boon, Veterinary Echocardiography, 1998
Rishniw M and Hollis NE, J Vet Intern Med 2000; 14:429-435
Hansson et al, Vet Rad and Ultrasound 2002
Bonagura et al. Echocardiography: principles of interpretation, Vet Clin North Am 15:1177, 1995

INTERPRETATION OF THE FINDINGS & FURTHER RECOMMENDATIONS

The cause of the clinical signs is pericardial effusion secondary to cardiac neoplasia associated with the right AV groove. The most likely tumor type given this location is a hemangiosarcoma (HSA). Other tumor types are less likely, including chemodectoma or ectopic parathyroid tumor. Regardless the patient is in cardiac tamponade secondary to hemorrhage from the tumor causing volume depletion and a drop in cardiac output. An immediate pericardiocentesis is indicated to stabilize the situation, and cytology of the pericardial fluid is recommended in search of a definitive diagnosis. **If this cannot be performed safely in your facility, immediate referral should be offered.** There is also evidence of dehydration/hypovolemia (small LVIDd, increase LV wall thickness/pseudohypertrophy) and aggressive fluid resuscitation is recommended.



PATIENT

Missy Ortell

SPECIES

Canine

BREED

Sheperd Mix

SEX

FS

AGE

13 years

WEIGHT

80lbs

INTERPRETED BY

Maggie Machen Lamy,
DVM, DACVIM
(Cardiology)

IMAGING PERFORMED BY

JK

HOSPITAL NAME

Hamburg VC

REFERRING VET

Dr. Branning

INVOICE

23661

DATE

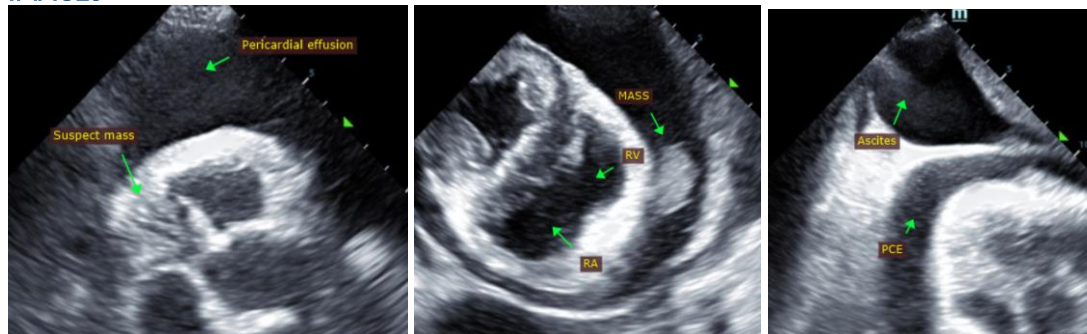
4/14/22

The prognosis with cardiac hemangiosarcoma is poor, with an MST of only 2-3 months. The emergent limiting factor is often recurrent hemorrhage, and a pericardial window or subtotal pericardiectomy may relieve clinical signs. Chemotherapy and/or radiation can also be discussed with an Oncologist and may extend average survival time. HSA also has a high metastatic rate, and full systemic screening is recommended for metastatic lesions. Patients with cardiac neoplasia are at high risk for recurrent hemorrhage and development of tamponade, malignant arrhythmias/sudden death in the future.

No cardiac medications are clearly indicated at this time. Over the counter herbal supplement Yunnan Baiyao may help decrease risk of bleeding, however true benefit is speculative (1 capsule PO BID).

Plan: Immediate pericardiocentesis, fluid resuscitation and ideally overnight monitoring. Once symptoms are relieved via pericardiocentesis and fluid resuscitation, a recheck of tumor dimension and fluid status can be considered in 1-2 months, sooner if recurrence of clinical signs.

IMAGES



The information and recommendations provided are based on the images presented by the referring veterinarian. No evaluation can be communicated regarding pathology that was not visible in the image/video clips provided.

Thank you for this referral. This report was generated using transcription software, and minor dictation errors may be present. If the clinical or image interpretation does not parallel your findings or if I can be of any further assistance please contact me.

Maggie Machen Lamy, DVM
Diplomate of the American College of Veterinary Internal Medicine (Cardiology)
info@sonopath.com